

THE HISTOLOGY OF THE BONE OF A PROSAUROPOD DINOSAUR

by J. D. CURREY

ABSTRACT. The histology of the long bone of a prosauropod dinosaur is described. The bone is in very good condition and is still birefringent like recent bone. The bone has a laminar histological pattern, quite unlike that of recent reptiles, but very like that of recent artiodactyls. The vascularization of the dinosaur bone is compared quantitatively with that of recent mammals and reptiles. The amount of vascularization is much greater than in recent reptiles, and is of the same order as, but rather more than, in recent mammals. It is argued that this may indicate physiological specialization in the dinosaurs.

THE histology of the bone of dinosaurs is of great interest because in a great many cases it shows convergence with that of the bone of recent mammals. This has been pointed out by Enlow and Brown (1957, p. 203) among others. They write: 'This dinosaur bone is composed of typical plexiform tissue, found characteristically in several mammalian groups, especially the artiodactyls. Rather than the predominant longitudinal direction of vascularization, the primary canals form a uniform, three-dimensional network.' It would appear, however, judging from their photographs, that this bone does not have a uniform three-dimensional network, but rather a series of two-dimensional networks, as described by Currey (1960). The purpose of this paper is to describe briefly the histology of the bone of a prosauropod dinosaur, which bone in one view at least looks very like the bone about which Enlow and Brown made the statement quoted above, and to compare the bone with the bone of some present-day reptiles and mammals, particularly the ox and the pig.

MATERIALS AND METHODS

Through the kindness of Dr. John Attridge, of Birkbeck College, I was able to obtain some pieces of bone from two species (so far unnamed) of prosauropod dinosaur. The site from which they were collected was Southcote Farm, Nyamandhlovu District, about 20 miles north-west of Bulawayo, Southern Rhodesia. The bones are from the Forest Sandstone Formation, which is the equivalent of the upper portion of the South African Red Beds. Their age, therefore, is Middle Upper Trias.

The bone was ground down to thin sections and examined unstained. The fossil bone was in good condition, and many histological features could be made out as clearly as in unstained undecalcified recent bone. Unless otherwise stated, the bone referred to in this paper was the cortical compact bone of the vertebral centrum.

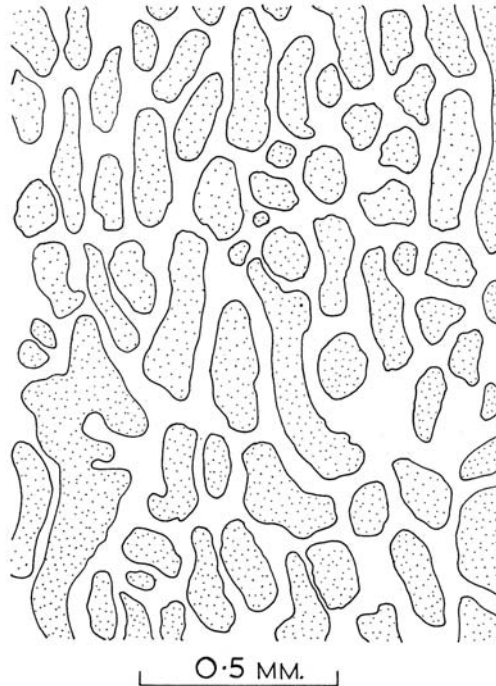
HISTOLOGY OF THE BONE

It is well known that the histology of different bones in the same animal, and of different parts of the same bone, differs greatly. For instance, the rib of the ox (*Bos taurus*) is composed mainly of Haversian bone, whereas the femur of the same animal is composed mainly of laminar bone, except under muscle insertions, where again the

[*Palaeontology*, Vol. 5, Part 2, 1962, pp. 238-46, pl. 36.]

bone is Haversian. Therefore, all the descriptions given here should not be thought necessarily to refer to all the bone in the animal, since in the main they refer to bone taken from one site only. Nevertheless, points of interest do emerge.

Examination of transverse (Plate 36, fig. 1), radial (Plate 36, fig. 2), and tangential sections (Plate 36, fig. 3), taken from sites adjacent to each other, shows that, in broad terms anyhow, the bone is laminar, as described by Currey (1960). That is to say, it



TEXT-FIG. 1. Camera-lucida drawing of a tangential section from the centrum of the vertebra of the dinosaur. Bony tissue is stippled. There is a two-dimensional network of blood-channels.

consists of a series of two-dimensional networks of vascular channels, sandwiched between thin layers of bone without blood-vessels. The blood-vessels when seen in tangential view show the network appearance typical of artiodactyls (Plate 36, fig. 3; text-fig. 1). It must be emphasized that these networks do not, in this part of the bone, extend in three dimensions. There is a tendency, more marked than in the ox or the pig (*Sus scrofa*), for the elements of the network to be elongated in one direction. In this case they are elongated in the direction parallel to the long axis of the vertebral centrum. There is no trace in these sections of remodelling of the bone.

The laminar bone of cattle usually has a very characteristic appearance. Each blood network is flanked by sheets of lamellar bone. Midway between successive blood networks, and flanked by the sheets of lamellar bone, is a sheet of woven bone. In the

middle of each sheet of woven bone is the 'bright line', whose exact nature is obscure, through which very few canaliculi pass. The laminar bone of these sections from the dinosaur vertebra does not show these clear distinctions between the various parts. There is no bright line. The osteocytes throughout the bone are more uniform in shape. In the highly developed laminar bone of artiodactyls the osteocytes in the woven bone are globular, while those in the lamellar bone are very flattened in the radial direction. In this dinosaur bone, however, the osteocyte lacunae seem to show a condition intermediate between that seen in lamellar bone and that seen in woven bone. There are, however, some very flattened lacunae. These do not seem particularly to occur near the blood networks, as they do in mammalian bone.

Woven bone seems not to be birefringent, whereas the lamellae found in laminar bone are alternately birefringent and non-birefringent. When seen by a polarizing microscope, therefore, laminar bone has a very striking appearance. When the laminae are arranged along the length of the axis of one of the polaroids, the bone is dark, and then, as the specimen is rotated, the lamellar part of the bone becomes bright, as does the bright line, while the woven bone remains dark whatever the orientation of the specimen. The transverse and radial sections of the dinosaur vertebra do not give this appearance. Instead it seems that the bone is birefringent throughout, unlike cattle bone, in which there are marked non-birefringent areas (Plate 36, figs. 4, 5). There is not the clear distinction between woven and lamellar bone. Furthermore, the birefringent bone of the dinosaur seems not to be clearly lamellated. There are, at the most favourable orientations, lighter and darker parts, but there are no clear lamellae. This is probably not due to the conditions of fossilization, because in the long bone of a prosauropod of a different species collected at the same site in Rhodesia, which I have also examined, there are Haversian systems that clearly show the lamellar structure characteristic of Haversian systems of recent forms; yet adjacent to these systems are parts of the bone that show the generalized birefringence shown in the bone of the vertebra (Plate 36, fig. 6).

EXPLANATION OF PLATE 36

Fig. 1. Transverse section of the vertebral centrum of the dinosaur. Unstained, direct light.

Fig. 2. Radial section of the same bone.

Fig. 3. Tangential section of the same bone.

Fig. 4. Transverse section of the vertebral centrum of the dinosaur, seen by polarized light.

Fig. 5. Transverse section of the femur of an ox, seen by polarized light. 'L': lamellar bone. 'BC': blood-channel. 'BL': bright line. 'W': woven bone. There is a large Haversian system just below the middle of the picture.

Fig. 6. Transverse section of the unidentified long bone of a prosauropod dinosaur, seen by polarized light. Two Haversian systems are visible, one in the middle and one in the bottom left-hand corner. A bright band of lamellar bone enclosing blood-channels is visible at the top of the picture. 'L': lamellar bone. 'BC': blood-channel.

Fig. 7. Transverse section of the unidentified long bone of a prosauropod dinosaur, seen by polarized light. There is a bright band of lamellar bone, not containing any blood-channels, running across the middle of the picture. Above this are sheets of lamellar bone enclosing blood-channels. At the bottom of the picture are more sheets of lamellar bone, but the blood-channels they enclose are off the bottom of the picture. 'L': lamellar bone. 'W': woven bone. 'BC': blood-channel.

The histology of this unidentified long bone, of another prosauropod dinosaur not of the same species, presents a different picture (Plate 36, fig. 6). The bone is arranged in laminae, but they are thicker, there being about $140\ \mu$ between successive blood-vessel nets, as opposed to $80\ \mu$ in the vertebra. A certain amount of reconstruction has gone on, so that there are Haversian systems scattered through the bone. These, as mentioned above, show very clearly the lamellar arrangement of typical Haversian systems. The laminae are less regular in their thickness and in their arrangement than in the vertebra. Whereas in the vertebral bone there seem to be no extensive sheets of woven bone, in this long bone sheets of it do occur. Woven bone is recognized by its non-birefringence, and the very globular appearance of the osteocyte lacunae. The woven bone usually occurs in the place characteristic of laminar bone: between successive blood networks, and separated from them by lamellar bone. Sometimes the thickness of birefringent bone is so slight as to give the appearance that the blood-channel network is bordered on one side by woven bone, though close inspection shows that this is not so. In places there is an indication of a bright line. The similarity to cattle bone is striking (Plate 36, figs. 5, 6). In many places there is a layer of birefringent bone sandwiched between two successive layers of woven bone, but not containing a blood network (Plate 36, fig. 7). This, as has been explained by Smith (1960), is probably owing to lamellar bone being laid down on the outside of the bone by the periosteum, instead of inside the primary cavities of woven bone. This phenomenon is seen occasionally in mammals, where it was reported by Smith.

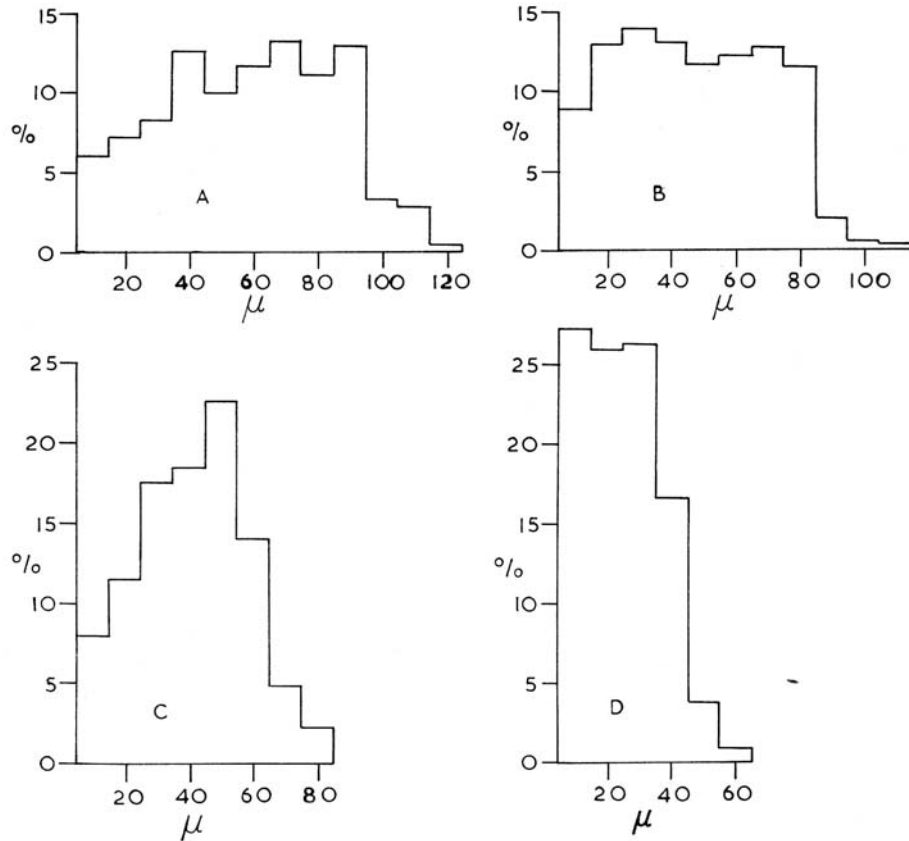
In general the arrangement of the laminar bone in the long bone is much more uneven than that of the laminar bone of the vertebra, the blood-channel networks (they are most probably networks, though no tangential section has been made) are farther apart, and some secondary reconstruction has occurred.

THE VASCULARIZATION OF THE BONE

It is apparent from the description above that the bone of these dinosaurs is in many respects very similar to that of some recent mammals. As such, it is an interesting case of histological convergence. We can reasonably assert that it is a case of convergence, because there is good evidence (Enlow and Brown 1957) that the pelycosaur, which may be taken as near-basal reptiles, had a relatively simple bone structure, without any complex system of two-dimensional vascular networks. It is therefore of interest to see to what extent the blood-supply of the dinosaur was similar to that of the artiodactyls in various respects.

Currey (1960) used the following parameters to give an idea of the efficiency of the blood-supply to the osteocytes in bone: distance of points taken at random from the nearest blood-vessel; area of blood-channel surface in unit volume of bone; volume of blood-channel in unit volume of bone; the distance between successive anastomoses in the blood-channel system. These parameters were used to express differences between Haversian and laminar bone from the same bone, namely the femur of the ox. However, since there may be differences between different bones in the same animal, the comparison is made here between the laminar bone found in the femur of a pig, the femur of an ox, the lumbar vertebra of an ox, and the vertebra of the dinosaur. Unfortunately, no tangential sections of the long bone of the dinosaur could be made so it was not possible to give an estimate of its vascularization, but it was almost certainly less than

that of the vertebra. The lumbar vertebra of an ox was chosen because it had a centrum that was of about the same size as the centrum of the dinosaur. The femur of the pig was chosen because it had the laminae close together, as had the dinosaur. The method by which information about the vascularity of the bone was obtained was the same as



TEXT-FIG. 2. Frequency histograms showing the distribution of distances separating points, taken at random, from the nearest blood-channel in various bones. Abscissa: distance from the nearest blood-channel. A, Ox femur. B, Ox vertebra. C, Pig femur. D, Dinosaur vertebra.

described previously (Currey 1960), except for certain minor changes, for instance, fifty rather than forty measurements were made of the breadth of the blood-channel in tangential view. For the femur of the pig and the vertebra of the ox, only fifty rather than a hundred measurements were made of the thickness of the channels in the radial plane, as this value was found to vary but little.

Text-fig. 2*a*, *b*, *c*, and *d* shows the intimacy of the vascular supply as measured by the

distance that 200 points, taken at random, are from the nearest blood-vessel. This can also be tabulated thus:

Distance from the nearest blood-channel that

	50 per cent.	90 per cent.	100 per cent. of osteocytes lie within.
Ox femur . . .	70 μ	100 μ	130 μ
Ox vertebra . . .	60 μ	90 μ	120 μ
Pig femur . . .	50 μ	70 μ	90 μ
Dinosaur vertebra . . .	30 μ	50 μ	70 μ

It can be seen from the figure and the table that the dinosaur bone has a much more intimate blood-supply than the ox bone, and a more intimate supply than the pig's femur. This is mainly because the laminae in the dinosaur's bone are closer together than are those of the ox. This is shown by the following:

Mean distance between laminae:

Ox femur . . .	190 μ
Ox vertebra . . .	150 μ
Pig femur . . .	100 μ
Dinosaur vertebra . . .	80 μ

The greater vascularity of the dinosaur's vertebra is shown again in the figures for the volume of blood-channel in the bone, and the total area of channel wall per cubic centimetre of bone.

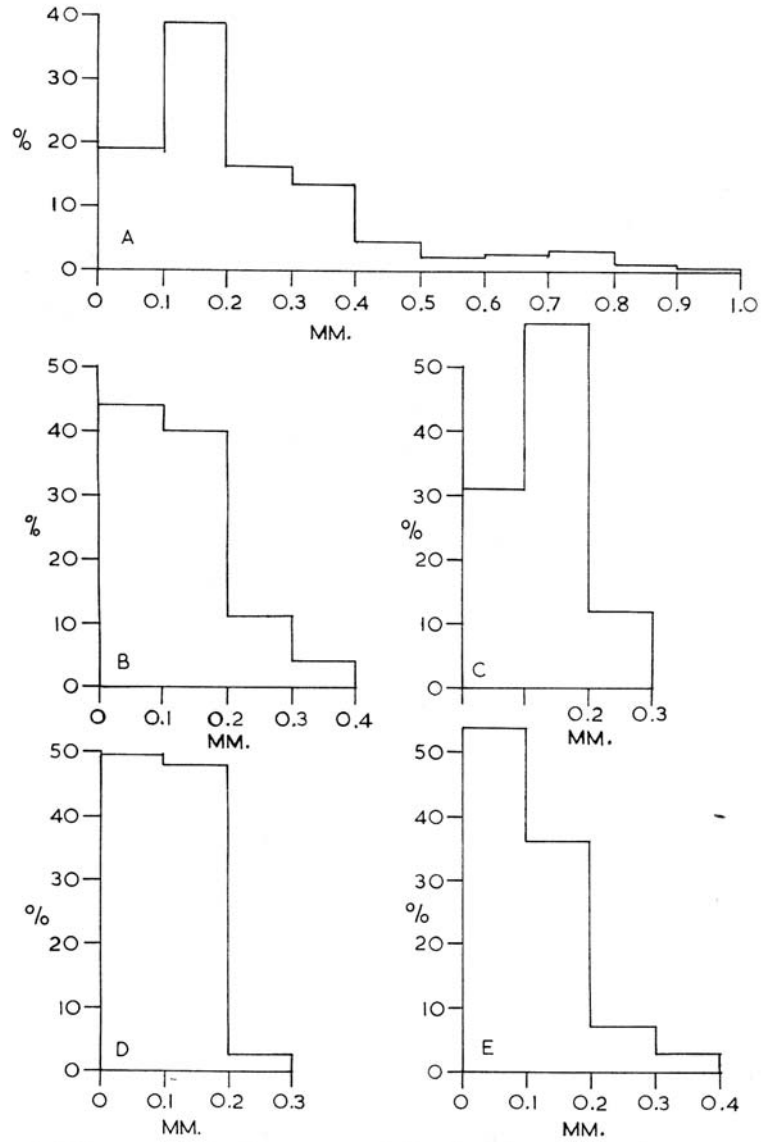
	<i>Volume of channel</i> Per cent.	<i>Area of channel wall per c.c.</i> sq. cm.
Ox femur . . .	1.40	32.9
Ox vertebra . . .	1.86	47.3
Pig femur . . .	2.13	56.7
Dinosaur vertebra . . .	8.65	155.2

The striking difference between the dinosaur and the other bones in these respects is due in part to the greater number of laminae per unit volume, but mainly to the much greater number of channels per unit volume. The dinosaur has about 19,000 cm. of channel per c.c., the ox femur has about 4,200 cm., the ox vertebra has about 9,600 cm., and the pig's femur has about 10,500 cm.

Text-fig. 3 shows the distance between successive anastomoses in the blood networks of the laminar bone in the femur of the ox, the vertebra of the ox, the femur of the pig, and the vertebra of the dinosaur, and also the distance between successive anastomoses in the Haversian bone of the femur of the ox. It can be seen that the distribution of anastomosis length is similar in all the laminar bone samples. This is despite the fact that there is so much more blood-channel volume in the dinosaur bone than in the other bones. The reason for this is that, as mentioned above, there is a tendency for the units of the network to be stretched out in the direction of the long axis of the centrum.

THE BLOOD-SUPPLY IN THE BONE OF OTHER REPTILES

These measurements and observations show that the bone of the dinosaur was similar to that of a modern artiodactyl in structure, but that it was more vascular. Before the significance of this can be considered, it is necessary to know whether these



TEXT-FIG. 3. Histogram showing inter-anastomosis length of channels in various bones. Abscissa: inter-anastomosis distance. A, Haversian bone of the femur of the ox. B, Laminar bone of the femur of the ox. C, Laminar bone of the vertebra of the ox. D, Laminar bone of the femur of the pig. E, Laminar bone of the vertebra of the dinosaur.

two characters are shared by other reptiles. An examination of the plates given by Enlow and Brown (1957) shows no laminar bone outside the mammals and dinosaurs, except in *Kannemeyeria*, an herbivorous dicynodont, an advanced mammal-like reptile but not on the line of evolution that gave rise to the mammals. Although Enlow and Brown have not studied every bone of every species of reptile, they have taken representatives of most groups, and it is quite clear that laminar bone is not common in reptiles.

It is more difficult to determine the amount of vascularization in reptile bone. Among the largest of the modern reptiles are the crocodiles. I have examined the neural arch of the axis vertebra and part of the nasal bone of a crocodile (*Crocodylus sp.*). In both bones there were parts that have blood-vessels, and other considerable parts without blood-vessels. The axis had a plate of bone about 0.6 mm. across, whose other dimensions were many millimetres, that was completely avascular. The nasal bone had a portion $2 \times 3 \times$ about 6 mm. without blood-vessels. The bones of the smaller Squamata are frequently completely avascular: the femur of a green lizard (*Lacerta viridis*) had a wall thickness of about 0.4 mm. in the middle of the shaft, and the bone here was completely avascular. Enlow and Brown (1957) report that even large lizards and snakes have bone that is almost entirely avascular. Similarly, the Chelonia do not usually have many blood-vessels in the bone.

It seems to be the case, then, that unlike the dinosaur bone, recent reptile bone is not remarkable for its great vascularity, in fact rather the reverse. The amount of blood-channel per unit volume in the dinosaur's bone is certainly exceptional for a reptile, except other dinosaurs, and is higher than that of recent mammals of comparable size.

DISCUSSION

Since so little is known concerning the reasons why bones differ so much at the histological level, it would be rash to speculate very much about the bone of the dinosaurs. However, it seems reasonable to assume that if a tissue has a similar form in two unrelated groups of animals, and does not have this form in other intermediate groups, then the tissue is responding to something that is present in these two groups and is absent elsewhere. Laminar bone is found in at least some members of the Mammalia, the dicynodonts and the dinosaurs. Similarly, bone that is little but a mass of Haversian systems is found in mammals, in a few birds, and in at least one dicynodont (*Dinodontosaurus*) (Enlow and Brown 1957, p. 206), and in dinosaurs. Dense Haversian bone is rarely found in small mammals. Laminar bone seems, in those major groups that show it at all, to be associated with an herbivorous way of life; thus the artiodactyls, the dicynodonts, and the prosauropod dinosaurs are all herbivores.

What particular character it was, shared by these groups, that caused the production of the similar kinds of bone pattern it is impossible to say. It is tempting to suppose that this highly organized bone reflects a correspondingly specialized metabolic organization, in particular the possession of homoiothermy. Certainly the dinosaurs were in many ways very advanced reptiles, and dicynodonts, though off the main line of evolution to the mammals, were also advanced. The skeletal characters proposed by Brink (1956) as indicating that some cynodonts (a group of mammal-like reptiles much more closely related than the dicynodonts to the ancestors of mammals) were warm-blooded cannot be used the other way round. For instance, Brink says that a clear distinction between the thoracic and the lumbar regions is evidence for diaphragmatic breathing, and hence

for a high metabolic rate. This may well be so but rhinoceroses, for example, do not have this clear distinction, yet are warm-blooded. It is impossible at the moment to state from an examination of the skeleton or of the histological structure of the bone whether the dinosaurs were homiothermic or not.

Until more evidence becomes available it must be sufficient to say that the dinosaur whose vertebra was examined had extremely well-vascularized bone, and that the bone was such as is found rarely elsewhere in vertebrates. It usually occurs in large, advanced herbivorous types, not among primitive reptiles, and not among small or carnivorous mammals. It is possible that this indicates some degree of physiological specialization in the dinosaurs greater than that seen in living reptiles.

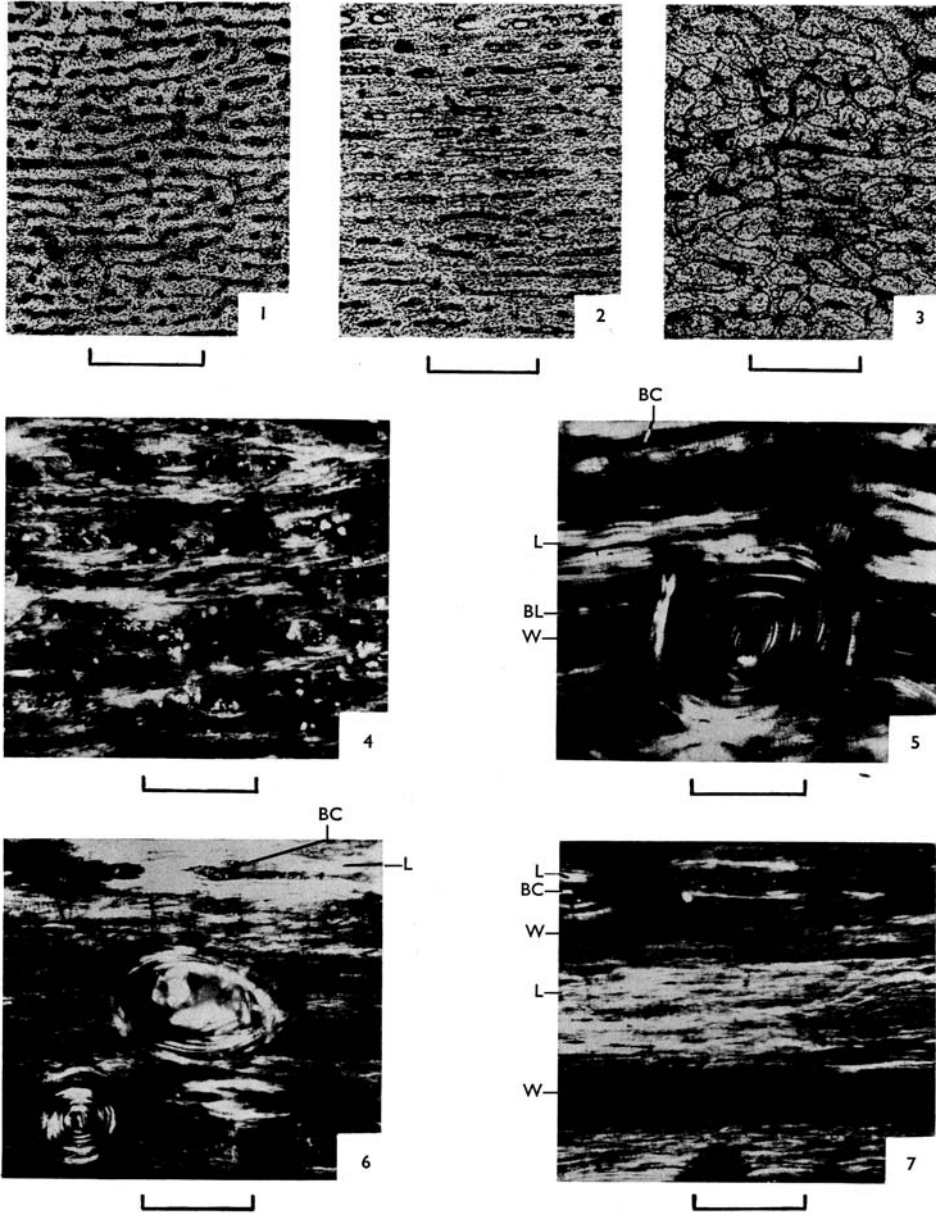
My thanks are due to Dr. J. Attridge for giving me the dinosaur bones upon which this paper is based, and also to Mr. H. K. Pusey and Dr. D. Nichols for their help and criticism.

REFERENCES

- BRINK, A. S. 1956. Speculations on some advanced mammalian characteristics in the higher mammal-like reptiles. *Palaeont. afric.* **4**, 77.
- CURREY, J. D. 1960. Differences in the blood supply of bone of different histological types. *Quart. J. Micr. Sci.* **101**, 351.
- ENLOW, D. H., and BROWN, S. O. 1957. A comparative histological study of fossil and recent bone tissues. Part 2. *Tex. J. Sci.* **2**, 186.
- SMITH, J. W. 1960. Collagen fibre patterns in mammalian bone. *J. Anat., Lond.* **94**, 329.

J. D. CURREY
Department of Zoology,
University Museum,
Oxford

Manuscript received 26 September 1961



CURREY, Prosauropod dinosaur

ADDENDUM

Plate 36 (Vol. 5, Part 2) : scale lines on figs. 1-3 represent 500μ ,
and those on figs. 4-7, 100μ .
